

LIGNOCAINE INFUSION FOR NEUROPATHIC ITCH IN PATIENT WITH NEUROFIBROMATOSIS

Mohd Mustafah N^{1,2}, Nik Nabil WN^{1,3}, and Ghazali AI¹.

¹Pain Management Clinic, Department of Anesthesiology and Intensive Care, Hospital Taiping, 34000 Taiping, Perak, Malaysia

²Department of Rehabilitation Medicine, Faculty of Medicine, Universiti Teknologi MARA, 47000 Sungai Buloh, Selangor, Malaysia

³Department of Anesthesiology and Intensive Care, Hospital Kuala Lumpur, Jalan Pahang, 50586 Kuala Lumpur, Malaysia

Correspondence:

Nadia Mohd Mustafah,
Department of Rehabilitation Medicine,
Faculty of Medicine,
Universiti Teknologi MARA,
47000 Sungai Buloh, Selangor, Malaysia
Email: nadiamustafah@gmail.com

Abstract

Neurofibromatosis (NF) is an autosomal dominant neurocutaneous disorder. The itchiness suffered by patients with NF is possibly caused by mast cells. However, transient receptor potential ankyrin 1 (TrpA1) and transient receptor potential vanilloid 1 (TrpV1) have been recently discovered as mediators of itchiness and pain in patients with NF. We reported a patient with NF, afflicted by neuropathic pain and itch, despite receiving conservative treatment. Herein, we provided the patient lignocaine infusion, which improved her pain and itch score by 50%. Additionally, her sleep quality, ability to perform housework and engagement in leisure activities were improved. This case report highlights the therapeutic value of lignocaine infusion when conservative treatment is ineffective for chronic neuropathic itch in patients with neurofibromatosis through suppressing TrpA1 and TrpV1.

Keywords: Neurofibromatosis, Lignocaine, Neuropathic Itch, TrpA1, TrpV1

Introduction

Neurofibromatosis is an autosomal dominant neurocutaneous disorder. The prevalence of pain in patients with neurofibromatosis pain ranges from 29% to 70% (1), with approximately 20% experiencing neuropathic itch (2). Neuropathic itch is typically treated with a cocktail of topical therapies, oral antihistamines, anticonvulsants, and antidepressants. Evaluating the effectiveness of pharmacologic treatment remains challenging due to the poorly understood etiology of neuropathic itch.

Of the available pharmacologic treatments, transdermal lignocaine has been found to have moderate quality evidence with an excellent safety profile for neuropathic pain (3). A randomized controlled trial involving patients with refractory neuropathic pain demonstrated that the short-term pain relief offered by lignocaine infusion therapy became prominent after repeated administrations. Noteworthy, no serious complications were observed with repeated administrations (4). Consistent with the trial findings, a retrospective study and two case reports supported that lignocaine infusion alleviated chronic itching in patients with advanced cutaneous T-cell lymphoma, and incomplete spinal cord injury following thoracic epidural abscess (5-7). To our knowledge, this

is the first case report on the management of chronic itchiness for neurofibromatosis.

Case report

We report the case of a 49-year-old woman with underlying neurofibromatosis Type 1 and dyslipidemia who suffered multisite pain for over 30 years without any precipitating events. The multisite pain was distributed across bilateral shoulders, bilateral upper extremities, upper and lower back, chest, abdomen, and left thigh. The sharp and electric-like pain was constant, involving different sites at a time, and was aggravated by prolonged lying, sitting, and walking. The prescribed Gabapentin 600 mg three times daily (TID) and Ultracet 1-2 tablets when necessary (PRN) provided no pain relief. During the consultation, she also complained of generalized itchiness without rashes or erythematous. She described the itchiness as a deep sensation, rather than superficial on her skin. The itchiness occurred throughout the skin (on parts with and without lesions). It was unrelieved with antihistamines (Loratadine 10 mg once daily and Chlorpheniramine 4 mg PRN) and aqueous cream with 1% menthol. She complained that the itchiness had consistently affected her work, social,

and leisure activities and occasionally disrupted her sleep (both in initiating and maintaining sleep).

The patient scratched continuously at various parts of the body throughout the consultation. Physical examination revealed generalized disseminated cutaneous and

subcutaneous neurofibromas of varying sizes on her face, neck, torso, and extremities, with scratch marks noted on the torso and limbs (Figure 1). Generalized muscle tenderness was present without joint tenderness, and the neurological examination was intact. Her pain Numeric Rating Scale (NRS) score was 4 out of 5.

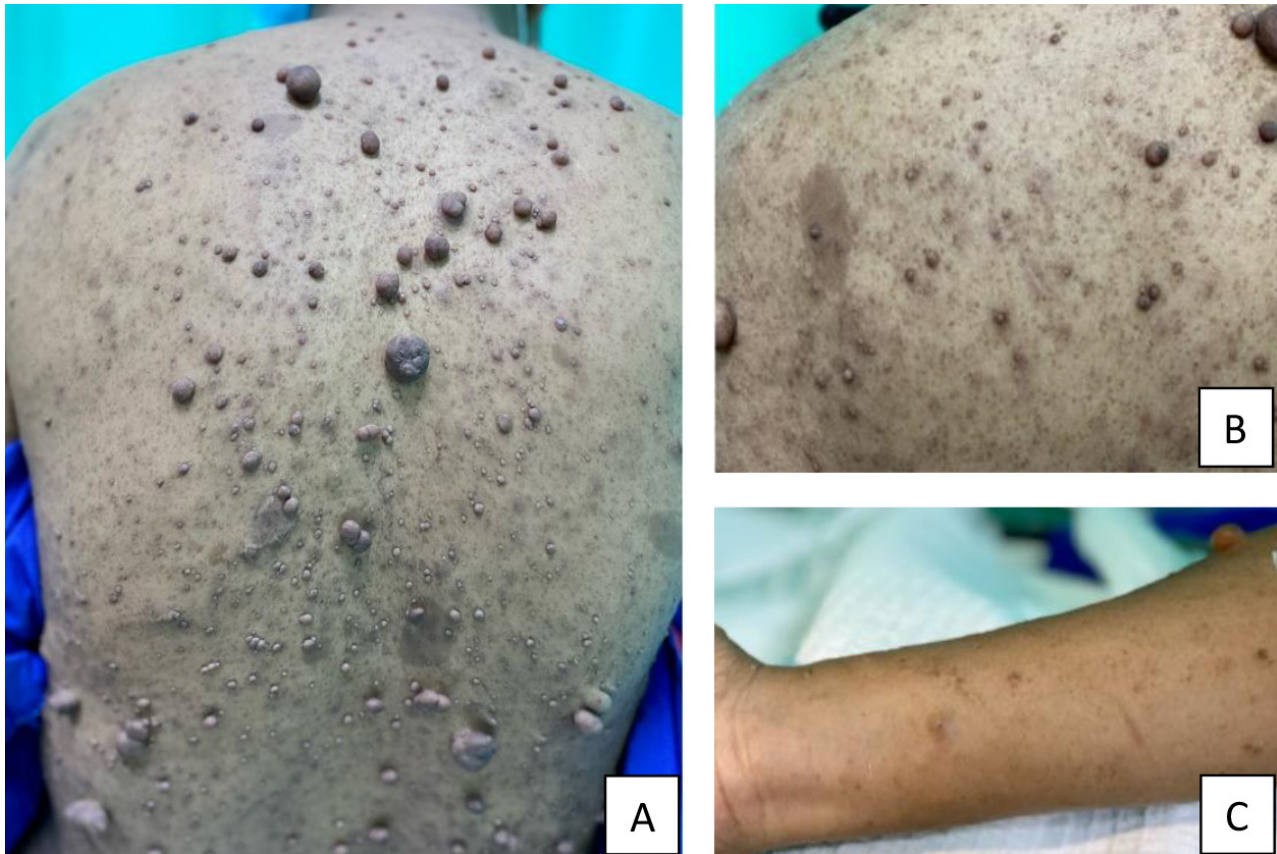


Figure 1: (A) Disseminated cutaneous neurofibromas of varying sizes; (B) café au lait spot, and (C) scratch marks.

During the initial consultation, considering the patient had been on Gabapentin of 1800 mg/day for over a year without symptom improvement, we switched her to Pregabalin 75 mg two times daily (BID). The trial was prompted by the knowledge that Pregabalin has better potency and bioavailability than Gabapentin. We also switched Ultracet to a regular dose of Tramadol 50 mg BID. However, after a month, there was no improvement in her pain score, and her itchiness had worsened. The patient agreed to our suggestion of lignocaine infusion to treat her neuropathic pain and itchiness. Table 1 describes the lignocaine infusion protocol used for her management based on the Pain Management Handbook 3rd Edition (8), along with a Numeric Rating Scale (NRS) for pain score and itchiness score.

Follow-up at two weeks and one month indicated that the patient's symptoms were persistently manageable, with pain and itch NRS of 3. Her symptoms no longer disturb her sleep, housework, and leisure activities.

Discussion

Mast cells have been previously suggested to cause itching in patients with NF1 (9), but a recent study has invalidated this by discovering that mast cells are sparsely distributed in NF1 (10). This is possibly the reason the antihistamine was ineffective for our patient. Contrarily, transient receptor potential ankyrin 1 (TrpA1) and transient receptor potential vanilloid 1 (TrpV1), which are expressed in both neural and immune cells, may mediate the symptoms of itch and pain in patients with neurofibromatosis (10), which likely the reason our patient responded to lignocaine infusion.

Lignocaine acts by inhibiting voltage-gated sodium channels and activating TRPV1 and TRPA1, resulting in more permeable and desensitized channels, ultimately producing an analgesic effect (11-13). Considering the generalized itchiness and pain that the patient suffered, we chose infusion over local application or transdermal patch.

Table 1: Infusion Protocol, Pain Score, and Itchiness Score

Day	Infusion Protocol	Pain Score		Itchiness Score	
		Pre-infusion	Post-infusion	Pre-infusion	Post-infusion
1	Bolus (1mg/kg): 70mg in 20cc over 5 minutes (3.5ml lignocaine 2% + 16.5ml NS)	8	4-5	> 10	8
2	Infusion (5mg/kg): 350mg in 50cc over 2 hours (17.5ml lignocaine 2% + 32.5ml NS) [†] *Patient's weight 70kg	6	3	8	3

[†]The protocol is according to the Pain Management Handbook 3rd Edition (8).

The point to ponder is whether repeated administration of lignocaine infusion is beneficial in reducing itchiness. Does lignocaine infusion provide a similar relieving effect as in neuropathic pain? To our knowledge, this is the first case report on managing chronic itchiness in patients with neurofibromatosis, as well as demonstrating the value of lignocaine infusion.

Acknowledgment

We would like to acknowledge KUP Nor Azuwa Junus for helping us throughout the procedure and record keeping.

Competing interests

The authors declare that they have no competing interests.

Ethical Clearance

We obtained the patient's written consent for the publication of this case.

Financial support

This case report received no specific grant from any funding agency in the public, commercial, or not-for-profit sectors.

References

- Bellampalli SS, Khanna R. Towards a neurobiological understanding of pain in neurofibromatosis type 1: mechanisms and implications for treatment. *Pain*. 2019; 160(5):1007-18.
- Khosrotehrani K, Bastuji-Garin S, Riccardi VM, Birch P, Friedman JM, Wolkenstein P. Subcutaneous neurofibromas are associated with mortality in Neurofibromatosis 1: A cohort study of 703 patients. *Am J Med Genet A*. 2005; 132A(1):49-53.
- Moisset X, Bouhassira D, Avez Couturier J, Alchaar H, Conradi S, Delmotte M, et al. Pharmacological and non-pharmacological treatments for neuropathic pain: Systematic review and French recommendations. *Rev Neurol (Paris)*. 2020; 176(5):325-352.
- Kim YC, Castañeda AM, Lee CS, Jin HS, Park KS, Moon JY. Efficacy and safety of lidocaine infusion treatment for neuropathic pain: a randomized, double-blind, and placebo-controlled study. *Reg Anesth Pain Med*. 2018; 43(4):415-24.
- McDonald JC, Spruyt O, Alhatem A. Control of intractable pruritus in a patient with cutaneous T-cell lymphoma using a continuous subcutaneous infusion of lidocaine. *J Pain Symptom Manage*. 2015; 49(4):E1-E3.
- Norris J, Barker J, Buelens O, Spruijt O. Does continuous subcutaneous infusion of lignocaine relieve intractable pruritus associated with advanced cutaneous T-cell lymphoma? A retrospective case series review. *Palliat Med*. 2019; 33(5):552-6.
- Chtompel Y, Eghtesadi M, Vargas-Schaffer G. A case report of refractory notalgia paresthetica treated with lidocaine infusions. *Am J Case Rep*. 2017; 18:1225-8.
- Medical Development Division. Pain Management Handbook 3rd Ed. Ministry of Health Malaysia. 2022. LATEST_FINAL_PAIN_MGT_HANDBOOK_3rd_Edition_MOH_-_05.01_.2023-comp_.pdf. Accessed 5 Jan 2024.
- Staser K, Yang F-C, Clapp DW. Mast cells and the neurofibroma microenvironment. *Blood*. 2010; 116(2):157-64.
- Rice FL, Houk G, Wymer JP, Gosline SJC, Guinney J, Wu J, et al. The evolution and multi-molecular properties of NF1 cutaneous neurofibromas originating from C-fiber sensory endings and terminal Schwann cells at normal sites of sensory terminations in the skin. *PLoS One*. 2019; 14(5):e0216527.
- Leffler A, Fischer MJ, Rehner D, Kienel S, Kistner K, Sauer SK, et al. The vanilloid receptor TRPV1 is activated and sensitized by local anesthetics in rodent sensory neurons. *J Clin Invest*. 2008; 118(2):763-76.
- Eberhardt M, Stueber T, de la Roche J, Herzog C, Leffler A, Reeh PW, et al. TRPA1 and TRPV1 are required for lidocaine-evoked calcium influx and neuropeptide release but not cytotoxicity in mouse sensory neurons. *PLoS One*. 2017; 12(11):e0188008.
- Elokely K, Velisetty P, Delemotte L, Palovcak E, Klein ML, Rohacs T, et al. Understanding TRPV1 activation by ligands: Insights from the binding modes of capsaicin and resiniferatoxin. *Proc Natl Acad Sci U S A*. 2016; 113(2):E137-45.